

## Complex Treatment of Dermatoses

1. Rahmatov Sardor

Received 25<sup>th</sup> Feb 2022,  
Accepted 10<sup>th</sup> Mar 2022,  
Online 20<sup>th</sup> Apr 2022

<sup>1</sup> Fergana Medical Institute of Public Health  
Department of Internal Medicine №2

**Abstract:** In recent decades, there has been a continuous increase in the number of patients with various allergic diseases, among which skin pathology is the most common. Often there is eczema in its various variants, urticaria, atopic dermatitis, diffuse neurodermatitis and a number of diseases, the etiopathogenetic factors of which include an allergic component, psoriasis, pruritus, collagenoses, etc. This article discusses the most common types of dermatosis and their treatment with new drug antihistamine action.

**Key words:** Dermatoses, microbial eczema, atopic dermatitis, food poisoning, acute urticaria, desloratadine.

### Introduction

Dermatoses is a group of diseases that has no age restrictions. There are many different types of dermatosis. The most common are dermatitis, eczema and psoriasis. Often, people are prone to skin lesions such as neurodermatitis, which develops in the case of neurological abnormalities, disruptions in the endocrine system, or weakened immunity. Another form of dermatosis is scabies. It most often occurs due to a weakened immune system. Many types of skin diseases occur as a result of damage to internal organs. Each type of dermatosis needs a separate treatment program [1].

With dermatosis, different parts of the body are affected. The development of diseases is influenced by both external (mechanical skin damage, the effect of plant poison, insect bites, etc.) and internal (allergies, infection, internal inflammation, metabolic problems) factors that affect to a greater or lesser extent on the human body. In addition, dermatosis can occur as a result of severe stress or any illness that affects the functioning of the immune system[2].

Lot of reasons for the occurrence of dermatoses, among which the main ones are: neurological abnormalities, disruption of the endocrine system, allergies, infectious diseases, metabolic disorders, weakened immunity as a result of infectious diseases, seasonal lack of vitamins, etc[3].

Symptoms of the disease appear at all stages of the disease, but depending on the age of the patient, they may differ:

1. In infancy, itching appears on the face, arms or legs (scabies dermatosis).
2. Allergic reactions most often occur in childhood.

3. In adolescence, acne usually appears on the face, and seborrheic dermatitis is also observed.
4. In old age, warts appear, skin integuments atrophy [4,5].

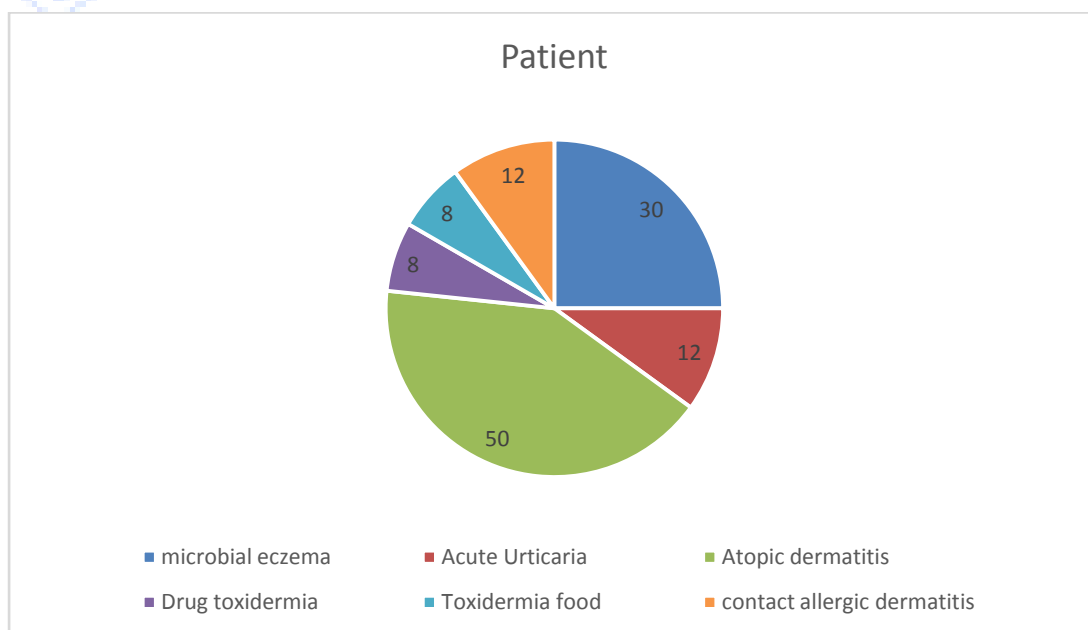
Fungal, viral, pustular and parasitic dermatoses can appear regardless of age. Depending on the clinical manifestation of skin pathology, it can be divided into 2 large groups [6]: 1 Diseases in which skin manifestations are mild, but general symptoms are observed (fever, weakness, etc.). 2 Diseases that are accompanied by itching, burning, numbness of the skin, the appearance of a rash on the skin, age spots[6,7].

These diseases usually do not pose a threat to life. However, the annual increase in the number of patients in all age groups, the adverse impact of diseases on the physical and psycho-emotional development of children, adolescents, adults, the lack of effectiveness of therapy determine the great social significance of improving the treatment of allergic dermatosis. Allergic diseases have a similar pathogenesis and can be considered as local manifestations of systemic allergic inflammation. The development of allergic inflammation is based on a whole cascade of various reactions. One of the main mediators of allergic reactions is histamine, therefore, blockers of H1-histamine receptors remain the means of choice in the treatment of allergic diseases. However, first-generation antihistamines do not suppress all allergy symptoms [8,9].

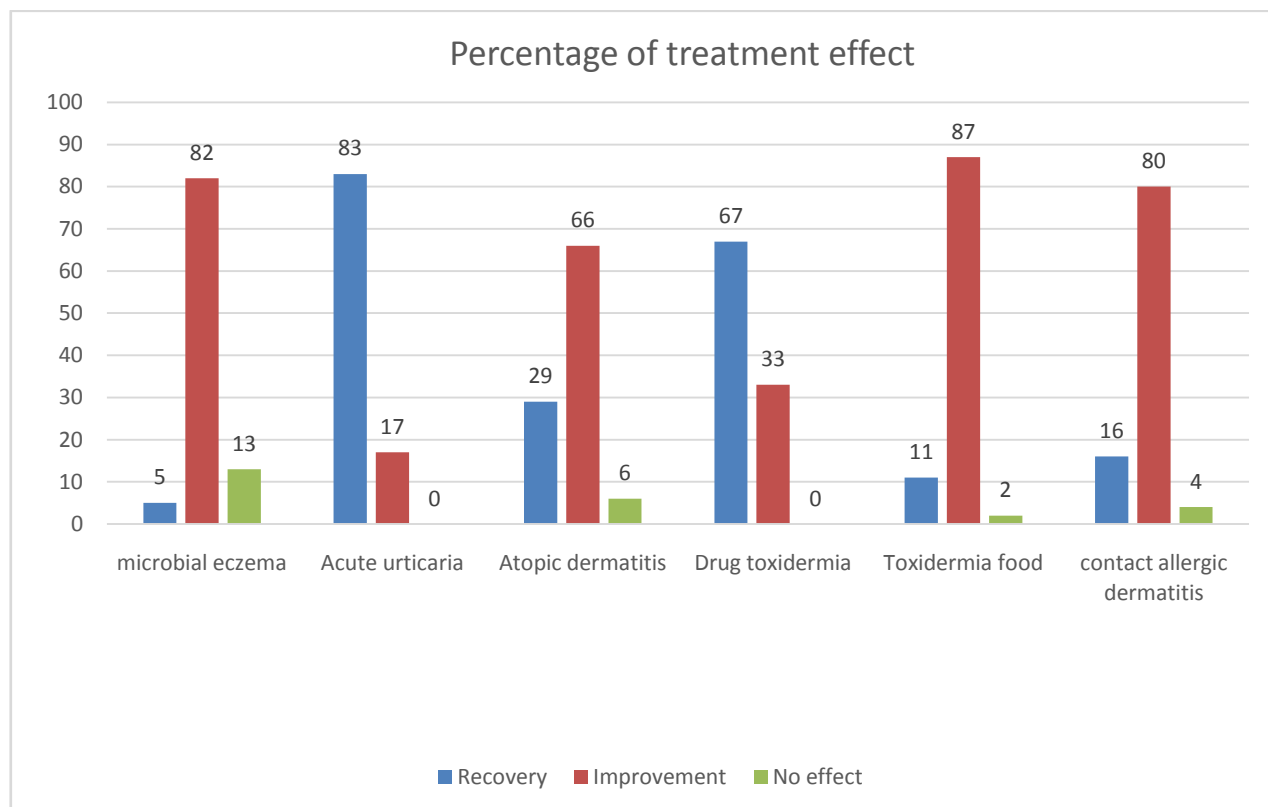
**The purpose of the study .** The aim of our study was to study the clinical efficacy and tolerability of treatment of patients with pruritic, allergic dermatoses with the second-generation antihistamine deslorathodine. Deslorathodine is an active metabolite of loratodine, exceeding its activity by 3-4 times. It inhibits many mediators involved in the development of systemic allergic inflammation and represents an almost ideal antihistamine drug with many positive properties.

**Materials and research methods.** The study was conducted in the city dispensary for skin and venereal diseases of the city of Fergana as part of the Department of Internal Medicine No. 2 during the period from September 2021 to March 2022. Under supervision there were 120 people suffering from microbial eczema (30), urticaria (12), atopic dermatitis (50), drug toxidermia (8), food toxidermia (8), contact allergic dermatitis (12). Patients received 10 mg of Desloratadine once daily for 2 to 3 weeks.

#### Research results.



In the majority of patients with microbial eczema, contact allergic dermatitis, toxidermia and atopic dermatitis, a significant reduction in itching, the cessation of new rashes, and the subsidence of inflammation on 3-4 days from the start of taking the drug were observed. By the end of the first week, the inflammatory process was insignificant, and by the end of 2-3 weeks recovery occurred in a certain part of the patients. In all patients with acute urticaria, a decrease in urticarial rashes was noted after the first dose of the drug. The itching disappeared in the first day. Only in 2 patients was observed sprinkling of urticarial elements after an error in the diet. Patients with atopic dermatitis and microbial eczema noted a good antipruritic and anti-inflammatory effect. In conditions accompanied by severe infiltration and proliferation (long-term microbial eczema, lichenoid stage of atopic dermatitis), the effect of using the drug desloratadine was more modest



**Conclusions** . Thus, desloratadine is a powerful selective blocker of histamine receptors, which has a pronounced effectiveness in acute inflammatory phenomena in the skin. The use of the 2nd generation antihistamine desloratodine in dermatological practice is advisable, first of all, in acute inflammatory processes, such as acute urticaria, and drug toxicoderma. For other types of dermatoses, desloratadine can be recommended as a complex treatment.

### Literature

1. Atopic dermatitis: Recommendations for practitioners. Russian national consensus document on atopic dermatitis / Ed. ed. Khaitova R.M., Kubanova A.A. - M., 2002.- 192 p.
2. Goryachkina L.A., Moiseev S.V. The role of Desloratodine( Erius ) in the treatment of allergic diseases // Clinical pharmacology and therapy . N.G.Korotkogo .- LLC "Provincial Medicine", 2001.- 520 p.
3. Dermatovenereology : National Guide / Yu.K. Skripkin, Yu.S. Butova, O.L. Ivanova. - M.: GEOTAR - Media, 2011. - 650 p.

4. Dermatovenereology : A textbook for medical schools / A.V. Samtsov, V.V. Barbinov . - St. Petersburg : SpecLit , 2008. - 252 p.: ill.
5. Dermatological reference book / A.T. Sosnovsky, N.Z. Yagovdik , I.N. Belugin. - 2nd ed., revised .and additional - Minsk: Higher School, 2001. - 448 p.
6. Dribnokhod , Yu.Yu. Cosmetology / Yu.Yu. Dribnokhod . - 6th ed. - Rostov-on-Don: Phoenix, 2010. - 532 p.
7. Zabarova , V.A. Plants - sources of essential and vegetable oils used in dermatology / V.A. Zaborova // Russian journal of skin and venereal diseases. - 2004. - No. 2 - S.71-72.
8. Skin and venereal diseases: Textbook / N.Z. Yagovdik , M.V. Kachuk , V.G. Pankratov. - Minsk: Higher School, 1999. - 126 p.

